

## N-Butyl Cyanoacrylate in Reshaping of Deformed Forehead in Patients with Plagiocephaly

Wael Mahmoud Khedr,<sup>1</sup> Amr Mohamed Madkour,<sup>1</sup> Ahmed Abdelrehem,<sup>2</sup> Mohamed Koraitim<sup>2</sup>

<sup>1</sup>Department of Neurosurgery, Faculty of Medicine, Alexandria University, Alexandria, EGYPT

<sup>2</sup>Department of Maxillofacial and Plastic Surgery, Faculty of Medicine, Alexandria University, Alexandria, EGYPT

Received: 5 March 2022 / Accepted: 30 June 2022 / Published online: 21 December 2022

**BACKGROUND:** Craniosynostosis is the premature fusion of one or more of the calvarial sutures, resulting in an abnormal head shape and increased intracranial pressure. Its incidence is estimated to be 1 in 2,000 births. Most of the cases are sporadic, with only 8% being syndromic or familial.

**OBJECTIVE:** The aim of the study was to evaluate the use of N-Butyl Cyanoacrylate in combination with sutures for fixation and maintenance of bone remodeling in patients who underwent surgery for anterior plagiocephaly.

**METHODS:** This retrospective study was conducted in two departments; Neurosurgery Department, and Maxillofacial & Plastic Surgery Department, Alexandria University, Egypt, including 19 patients who underwent surgery for correction of plagiocephaly between January 2015 and January 2020. N-Butyl Cyanoacrylate was used in combination with 2-0 polydioxanone suture as a method for maintenance of bone remodeling in the operated subjects. Surgical outcome was assessed by the expanded Whitaker classification and the degree of parental satisfaction.

**RESULTS:** The mean age at surgery was 6.47 months and the mean follow-up period was 24 months with a minimum of 18 months follow-up. None of our patients had major complications. One patient had infection postoperatively that resolved in two weeks. According to the Whitaker grading, 13 patients had excellent results and classified as “Whitaker grade I”, 4 patients had slight supraorbital elevation and 2 patients had an ipsilateral temporal constriction “Whitaker grade IIA”, but no further intervention was done. None of our patients required reoperation for correction of a surgical relapse.

**CONCLUSION:** Fronto-orbital advancement with slight overcorrection, together with the use of N-Butyl Cyanoacrylate for maintenance of bone shape after remodeling and bone fixation are safe and provide satisfactory and stable aesthetic results.

**KEYWORDS:** Coronal suture synostosis, Cyanoacrylate, Fronto-orbital advancement, Plagiocephaly.

### INTRODUCTION

Craniosynostosis is the premature fusion of one or more of the calvarial sutures, which causes an irregular skull shape and can lead to increased intracranial pressure, which can cause blindness and mental retardation. It is believed that 1 in every 2,000 newborns is affected. Most of the cases are simple, with only 8% being syndromic or familial.<sup>1</sup> True synostosis necessitates surgical intervention and should be differentiated from positional plagiocephaly, which develops as a result of sleeping in the supine position during infancy and is treated conservatively with positional treatment or a molding helmet.<sup>2</sup>

Until Tessier popularized frontal bone repositioning for the aim of cranial volume expansion in the 1960s,<sup>3-5</sup> linear craniectomy was recorded as the first surgical procedure for opening the fused suture in the 1890s. Since then, a number of craniosynostosis surgical procedures have been created based on numerous ideas.<sup>6-8</sup> The goal of craniosynostosis

surgery is to reduce intracranial pressure while also improving the shape and symmetry of the skull.

Strip craniectomy or lateral canthal advancement often fails to produce long-standing correction in the orbital position or cranial symmetry.<sup>9</sup> Therefore, open cranial vault remodeling with fronto-orbital advancement has been developed as the gold conventional technique for correction of anterior plagiocephalic cases.<sup>10-12</sup> This technique involves removal of the entire frontal bone and partial parietal craniectomy followed by removal, recontouring and advancement of supraorbital rims.

Following the established techniques for fixation described by Whitaker and Bartlet for unilateral synostosis, the bone is fixed in its new architectural location with a combination of resorbable plates, screws, sutures, and wires.<sup>12</sup>

Frontal plagiocephaly, the premature fusion of unilateral coronal suture, is widely understood to represent the most complex set of craniofacial deformity.<sup>13</sup> Unicoronal synostosis or anterior plagiocephaly is characterized by asymmetry of the facial axis and orbits. Therefore, the aim of surgery is to achieve symmetry by bending the recessed side and straightening the overprojected side of

### Correspondence:

Wael Mahmoud Khedr  
Department of Neurosurgery, Faculty of Medicine, Alexandria University, Alexandria, Egypt  
Email: waelkhedr2000@yahoo.com

the entire frontal bone and the fronto-orbital bandeau, in addition to Barrel-stave osteotomies in the parietal and/or temporal bones.<sup>14,15</sup>

The calvaria in children grow by resorption of the inner table and new bone formation on the outer table. This leads to migration of the steel wire and non-resorbable plates used for fixation and can progress onto the dura and the brain.<sup>16</sup>

Several reports have demonstrated the use of absorbable plates in pediatric craniofacial surgery with no risk of migration and fewer potential complications than the traditional use of metal plates, screws and wires. However, the higher cost of absorbable plates was a considerable limitation.<sup>17</sup>

Cyanoacrylate is a surgical glue which polymerizes rapidly following contact with proteinaceous surfaces. They have several surgical applications as wound closure, fistulae obliteration, skin graft fixation, arterio-venous malformations, and other surgical applications.<sup>18-22</sup>

The aim of the current study was to evaluate the use of N-Butyl Cyanoacrylate (NBCA) in combination with suturing for fixation and maintenance of bone remodeling in anterior plagiocephalic cases.

## PATIENTS AND METHODS

This retrospective study was conducted in two departments; Neurosurgery Department and Maxillofacial & Plastic Surgery Department, Alexandria University, Egypt. It included all subjects who underwent surgery for correction of plagiocephaly from January 2015 until January 2020. An informed written consent was obtained from all patients' guardians. The principles outlined in the Declaration of Helsinki were followed in this study. The study was approved by the Ethics Committee of the Faculty of Medicine of Alexandria University (institutional review board (IRB) No.: 00012098, FWA No.: 00018699). Additionally, the study was performed according to the Strengthening of Reporting of Observational Studies in Epidemiology (SROBE) statement.

In this study, HistoacrylR tissue adhesive (B. Braun, Aesculap, Germany) was used in combination with

2-0 polydioxanone suture (PDS) as a method for maintenance of bone remodeling in the operated subjects instead of the conventional method using wires for fixation of the osteotomized cranial bones.

## Inclusion criteria

1. Patients presenting at an early age (1- 12 months).
2. Subjects who underwent surgical correction of simple anterior plagiocephaly using cyanoacrylate for gluing the bone segments together in combination with 2-0 PDS material.
3. Subjects with higher degrees of compliance who presented at all follow-up appointments.

## Exclusion criteria

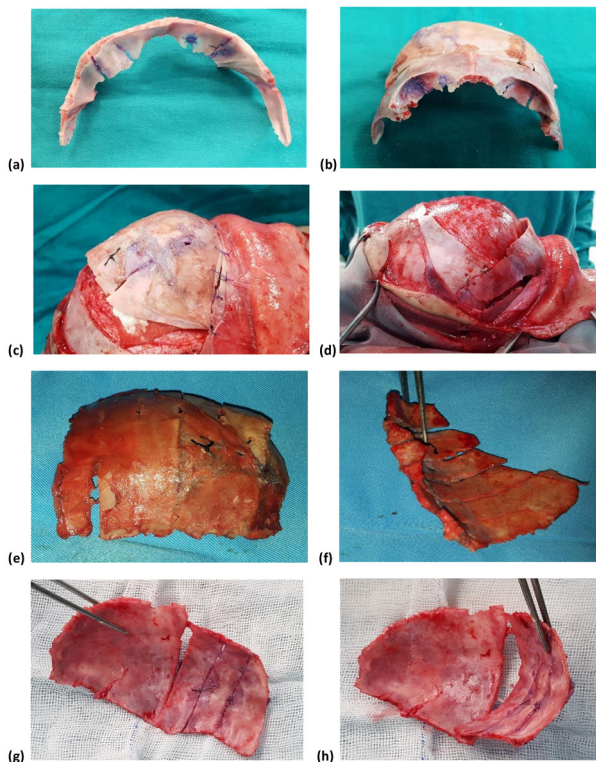
1. Patients presenting at an older age more than 1 year.
2. Poor compliance with missed appointments.

## Surgical technique

Under general anesthesia, a wavy coronal incision was used in all patients. An anterior scalp flap was then dissected in the subgaleal plane and the periosteum was incised 1 cm ahead of the supraorbital rim and the dissection was continued in sub-pericranial plane to protect the supraorbital neurovascular bundle. Temporalis muscle was dissected free from the temporal fossa bilaterally to the level of the zygomatic arch. A small rim of temporalis muscle and fascia were kept attached to the temporal fossa. A one cm fronto-orbital bandeau was then developed after performing a bifrontal craniotomy. A tongue-in-groove was designed with its posterior part at a higher level than anterior. This would result in positioning of the ipsilateral supraorbital ridge at a lower level after advancement.

After removal of the bandeau, it was contoured by bending (removal of wedges) of the recessed side, while straightening (scoring) of the over-projected side. The new contour was maintained through application of HistoacrylR tissue adhesive on the sites in combination with 2-0 PDS where the wedges were removed and the bone was scored (**Fig. 1**). Barrel-staving osteotomy was placed in the frontal/parietal/ temporal bones for the purpose of reshaping which was maintained by the application of HistoacrylR (**Fig. 1**). The supraorbital bar was then repositioned back in a hypercorrected position (the affected side was more anterior and lower than the contralateral side).

The temporalis muscle and fascia were then sutured to the residual rim of muscle and fascia attached to the temporal bone. On the affected side, the muscle was rotated anteriorly to fill the newly reconstructed temporal fossa. The scalp flap was then flipped back to check for symmetry, advancement and temporal hollowing. When the results were satisfactory, the coronal incision was then closed in layers after inserting a suction drain.



**Fig 1:** (a,b) Intra-operative supraorbital bar frontal and upper views (a patient with right-side frontal plagiocephaly). A new contour was maintained through application of HistoacrylR tissue adhesive on the wedges which were removed in the ipsilateral side (the right flattened supraorbital bar side) beside application of sutures to increase and augment the convexity of the flattened right side, while on the contralateral side the bone was slashed and overextended to decrease the convexity of the left bulged supraorbital bar side. This allows orbital symmetry and ease in obtaining the correct supraorbital convexity. (c) Intraoperative view shows stabilization of the supraorbital bar, frontal bone, parietal bone, and temporal bone using 2-0 PDS material, after correction of the right sided unilateral coronal synostosis, using a bifrontal barrel-staving osteotomies combined with orbital osteotomies. (d) Intraoperative view shows 'tongue in groove' advancement of the fronto-orbital bandeau, using wires for stabilization. (e,f) Molding of osteotomized bone on the table, by bending the ipsilateral frontal bone after doing the barrel-stave osteotomies for reshaping, keeping the periosteum in place and then maintaining its contour by application of HistoacrylR. (g,h) Molding of osteotomized bone on the table, by bending the ipsilateral frontal bone after doing the barrel-stave osteotomies for reshaping, and then maintaining its contour by application of HistoacrylR, while the contralateral side is straightened.

### Evaluation and follow up

All patients were followed up at 1 week, 1 month, 3 months, 6 months and 1 year after surgery. Surgical outcomes including cranial vault and forehead shape/symmetry, position of the ipsilateral supraorbital rim and complications were all recorded. Surgical outcome was assessed by:

1. The expanded Whitaker classification<sup>23</sup> (Table 1);

a simple method based on the aesthetic outcome and whether a further intervention is needed.

2. The degree of parental satisfaction and cosmetics which entails the use of ten point visual analogue scale (VAS) assessment graded from one to ten (1 = very bad aesthetics, 10 = excellent prognosis) preoperatively, and at 1 week, 1 month, 3 months, 6 months, and 1 year postoperatively. Then, the mean of the VAS of each postoperative data was compared statistically with the preoperative one.

### Statistical analysis

Using a specially constructed sheet on Microsoft Excel, data was entered, thoroughly revised, and transferred to IBM statistical package for social sciences (SPSS) version 17.0 (SPSS Inc., Chicago, IL, USA). For descriptive statistics, the mean and standard deviation were calculated.

### RESULTS

A total of 19 patients (11 girls and 8 boys) with non-syndromic plagiocephaly were included in this study. The mean age was 6.47 months (range; 1–12 months). Right coronal synostosis (10 cases) was slightly more common than left coronal synostosis (9 cases) (Table 2). HistoacrylR was used to stabilize the supraorbital bar, frontal bone, parietal bone, and temporal bone in combination with 2-0 PDS material in all patients (Fig. 1). The mean duration of hospital stay was 4.7 days (range 3–7 days). The mean follow-up period was 24 months (range 1- 5 years).

There were no acute perioperative complications such as septic infection, surgical wound dehiscence, or collapse of the remodeled forehead. There were no deaths due to hypothermia or hypovolemia. One patient had an infection overlying one of the wires used for fixation which was managed by oral antibiotics and subsequent removal of the wire. None of our patients had any evidence of adverse inflammatory reaction to cyanoacrylate.

The parental verbal response regarding cosmetics was excellent by the third month postoperative interval as evident from the mean VAS scores. By the end of the study, all were satisfied with the cosmetic outcome (Fig. 2). Thirteen patients (68.4%) were classified as "Whitaker grade I" as they had dramatic improvement in their appearance with more symmetrical skull, which was maintained throughout their follow-up period. Six patients (31.6%) were classified as "Whitaker grade IIA". Four patients had slight supraorbital elevation, and 2 had ipsilateral temporal constriction (Table 2). This appeared 7-9 months postoperatively, but no further intervention was done. None of our patients required reoperation for correction of a surgical relapse. Although long-term results might be different, but short term follow-up showed acceptable shape and family satisfaction.

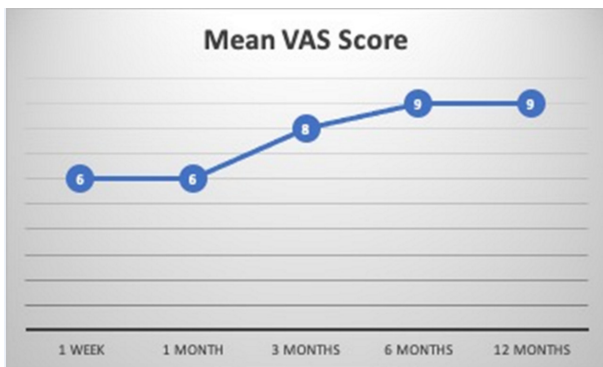


Fig 2: Mean VAS scores showing excellent results by the third month postoperatively.

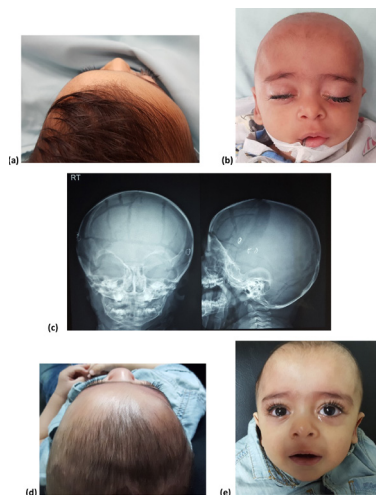

Fig 3: (a,b) Preoperative cranial and frontal views of a boy show right plagiocephaly showing flattened right forehead and mild raised supra-orbital ridge. (c) Postoperative plain X-ray (anteroposterior and lateral views) show bilateral barrel stave osteotomies and fronto-orbital bandeau advancement. (d,e) Postoperative cranial and frontal views show an excellent surgical outcome 6 months after correction.

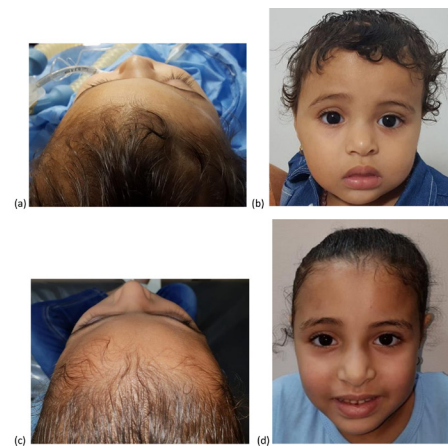

Fig 4: (a) Preoperative cranial view of a girl shows right plagiocephaly with a flattened right forehead and an overgrowth of the left forehead. (b) Postoperative frontal view after 3 months shows symmetrical bilateral frontal bones, but still raised right supra-orbital ridge. (c,d) Postoperative cranial and frontal views show an excellent surgical outcome after 4 years of correction with both supra-orbital ridges almost even.

Table 1: Expanded Whitaker Classification Definitions<sup>23</sup>

Grades	
I	No refinements or surgical revisions considered advisable or necessary by the surgeon or the patient.
IIA	Minor imperfections noted, but no surgical revision performed or planned
IIB	Minor imperfections that required minor soft tissue or bone contouring revisions
III	Major alternative osteotomies or bone-grafting procedures needed or performed.
IV	Major procedure duplicating or exceeding in extent the original surgery necessary.

Table 2: Sex distribution, laterality, and postoperative Whitaker classification of the included patients

	No of cases	Male	Female	Right	Left	Whitaker class				
						I	IIA	IIB	III	IV
Number	19	8	11	10	9	13	6	-	-	-
Percentage	100%	42%	58%	52.6%	47.4%	68.4%	31.6%			

## DISCUSSION

Bioabsorbable plating system provides a rigid fixation and avoids many complications associated with titanium plates and wire fixation, which include hardware palpability, higher risk of infection, intracranial migration and the need for second procedure for removal.<sup>16,24</sup> However, this bioabsorbable plating system is expensive and its cost was not affordable to most of our patients.

In the current study, we emphasize on the use of cyanoacrylate together with 2-0 PDS for maintenance of the new bone contour. NBCA is a monomer which polymerizes rapidly in presence of ionic substances such as blood or tissue fluids and has an excellent tensile strength, in addition to being very effective in closing surgical or wound incisions. It can rapidly transfer from a liquid to a solid state at room temperature without the need of catalysts or solvents or any pressure application. Although NBCA has bacteriostatic properties, the direct tissue toxicity when applied may compromise the host immunity and increase the risk of infection.<sup>25</sup>

In our series, we used 2-0 PDS in addition to cyanoacrylate, which make the suture material harder, maintain the reshaped bone parts adherent to each other longer, and keep these bone parts in their new position till fusion. This leads to sound bone fixation and good aesthetic results. We used wires in addition to sutures for fixation in two patients, where one case showed superficial skin infection. Therefore, we do not recommend its use due to the risk of infection and wire migration.

It is important to carefully consider the heat production of the polymerization reaction of cyanoacrylate. We tried to minimize this by careful application of cyanoacrylate drop by drop with isolation from the surrounding tissues with ointment and gauze.

The use of tissue adhesive has been tried in different medical subspecialties with reported high success rates. Closure of facial wounds is considered as the most common indication of cyanoacrylate which can be used alone or in addition to conventional sutures as in oncological surgery. Also, its use was reported in skin graft fixation with perfect results. Similarly, many reports documented the success of its use in the management of corneal perforations, stabilization of implants, cerebrospinal fluid leak, gastric varices and arteriovenous fistulae.<sup>18-22</sup>

In their experimental study, Akcal et al. found that cyanoacrylate can be used safely in the management of bone fracture without any adverse effect on healing.<sup>26</sup> Gonzalez et al. reported the success of using cyanoacrylate for fixation of the cranial bones following craniotomy,<sup>27</sup> while Foresta et al. used the glue for fixation of the anterior wall of the maxillary sinus comminuted fractures.<sup>28</sup>

In our study, we introduced the combined usage of both surgical sutures augmented with application of tissue

adhesive cyanoacrylate, for fixation and maintenance of the bones remodeled in the management of anterior plagiocephalic cases. This is relatively a new application, which has the advantages of relatively firm fixation by the suture materials that became more fixed with the application of tissue adhesive cyanoacrylate that solidifies over the resilient suture material leading to hardening of the sutures with resulting firmer fixation. The application of the adhesive immediately after knotting the sutures leads to hardening of the suture material in the favored position which adds to the bone stability.

In our study we did not face the disadvantage of the palpability of the plating system and its visibility under the skin for several months postoperatively, which was particularly important to the patients' families, whether metal or absorbable system. Eppley et al. reported that the system of the absorbable plates was felt and seen under the skin for a long time (9 to 18 months) till complete resorption.<sup>29</sup>

On the other hand, our patients also avoided the disadvantage of the growth restriction and the implant migration of the metal plates to the inner table of the skull, which often requires reoperation for plate and screw removal as stated by Orringer et al.<sup>30</sup>

Another complication which was not a disadvantage in our study is the break down and the indentation of the implants through the skin especially around the areas of thinner skin like the forehead and nasal bridge. This emphasizes the usage of the available periosteum and temporal muscle to provide soft tissue coverage of the implant.

The current study demonstrated the use of cyanoacrylate glue for maintenance of bone shape after remodeling and bone fixation revealing satisfactory and stable aesthetic results. From the results of this study, we believe that cyanoacrylate when combined with sutures can be an alternative choice for resorbable plates and other methods of fixation especially in developing countries, where the cost is an important determinant.

### Limitations of the study

The main limitation of our study was the relatively small number of patients, since our study only discussed the anterior plagiocephalic cases. Although the number of patients included in our study was 19 cases, this is still considered a small number when compared to other published studies discussing similar topics. Further studies incorporating a larger number of patients with a longer follow-up period is justified to confirm or refute our findings.

## CONCLUSION

In our study, we demonstrated that the combination of fronto-orbital advancement with slight overcorrection and the use of the glue for maintenance of bone shape after remodeling and bone fixation have satisfactory and stable aesthetic results. Although resorbable plates were

reported to be excellent when used for bone fixation in craniostylosis surgery, we believe that cyanoacrylate when combined with sutures can be an alternative choice especially in developing countries, like Egypt, where cost is an important determinant.

#### List of abbreviations

IRB: Institutional review board.

NBCA: N-butyl cyanoacrylate.

PDS: Polydioxanone suture.

SPSS: Statistical package for social sciences.

STROBE: Strengthening the Reporting of Observational studies in Epidemiology.

VAS: Visual analogue scale.

#### Disclosure

The authors report no conflict of interest in the materials or methods used in this study or the findings specified in this paper.

#### Funding

The authors received no financial support for the research, authorship, and/or publication of this paper.

#### References

- Di Rocco F, Arnaud E, Renier D. Evolution in the frequency of nonsyndromic craniostylosis. *J Neurosurg Pediatr.* 2009;4:(1)21-25.
- Anantheswar YN, Venkataramana NK. Pediatric craniofacial surgery for craniostylosis: Our experience and current concepts: Part -1. *J Pediatr Neurosci.* 2009;4(2):86-99.
- Alvarez-Garijo JA, Cavadas PC, Vila MM, Alvarez-Llanas A. Sagittal synostosis: Results of surgical treatment in 210 patients. *Childs Nerv Syst.* 2001;17(1-2):64-68.
- Tessier P, Delaire J, Billet J, Landais H. Considerations on the development of the orbit; its incidences on facial development. *Rev Stomat.* 1965;66:27-39.
- Tessier P, Guiot G, Rougerie J, Delbet JP, Pastoriza J. Cranio-naso-orbito-facial osteotomies. Hypertelorism. *Ann Chir Plast.* 1967;12(2):103-118.
- Barritt J, Brooksbank M, Simpson D. Scaphocephaly: Aesthetic and psychosocial considerations. *Develop Med Child Neurol.* 1981;23(2):183-191.
- Mohr G, Hoffman HJ, Munro IR, Hendrick EB, Humphreys RP. Surgical management of unilateral and bilateral coronal craniostylosis: 21 years of experience. *Neurosurgery.* 1978;2(2):83-92.
- Nishimoto H, Makiyama Y, Nishimura J, Watanabe S: Long-term surgical results of craniostylosis and its related therapeutic problems. *Jpn J Neurosurg.* 2001;10:92-98.
- Panchal J, Marsh JL, Park TS, Kaufman B, Pilgram T, Huang SH. Sagittal craniostylosis outcome assessment for two methods and timings of intervention. *Plast Reconstr Surg.* 1999;103(6):1574-1584.
- Sabry MZ, Wornom IL 3rd, Ward JD. Results of cranial vault reshaping. *Ann Plast Surg.* 2001;47(2):119-126
- Cohen SR, Holmes RE, Ozgur BM, Meltzer HS, Levy ML. Fronto-orbital and cranial osteotomies with resorbable fixation using an endoscopic approach. *Clin Plast Surg.* 2004;31(3):429-442.
- Whitaker LA, Bartlett SP. The craniofacial dysostoses: Guidelines for management of the symmetric and asymmetric deformities. *Clin Plast Surg.* 1987;14:(1):73-81.
- David LR, Fisher D, Argenta L. New technique for reconstructing the affected cranium and orbital rim in unicoronal craniostylosis. *J Craniofac Surg.* 2009;20(1):194-197.
- Seruya M, Oh AK, Boyajian MJ, et al. Long-term outcomes of primary craniofacial reconstruction for craniostylosis: A 12-year experience. *Plast Reconstr Surg.* 2011;127(6):2397-2406.
- Taylor JA, Paliga JT, Wes AM, et al. A critical evaluation of long-term aesthetic outcomes of fronto-orbital advancement and cranial vault remodeling in nonsyndromic unicoronal craniostylosis. *Plast Reconstr Surg.* 2015;135(1):220-231.
- Fearon JA, Munro IR, Bruce DA. Observations on the use of rigid fixation for craniofacial deformities in infants and young children. *Plast Reconstr Surg.* 1995;95(4):634-638.
- Eppley BL, Morales L, Wood R, et al. Resorbable PLLA-PGA plate and screw fixation in pediatric craniofacial surgery: Clinical experience in 1883 patients. *Plast Reconstr Surg.* 2004 15;114(4):850-857.
- Penoff J. Skin closures using cyanoacrylate tissue adhesives. Plastic surgery Educational foundation DATA committee. Device and technique assessment. *Plast Reconstr Surg.* 1999;103(2):730-731.
- Chang CJ, Hou MC, Lin HC, et al. The safety and probable therapeutic effect of routine use of antibiotics and simultaneously treating bleeding gastric varices by using endoscopic cyanoacrylate injection and concomitant esophageal varices with banding ligation: A pilot study. *Gastrointest Endosc.* 2010;71(7):1141-1149.
- Hida K, Yamaguchi S, Seki T, et al. Nonsuture dural repair using polyglycolic acid mesh and fibrin glue: Clinical application to spinal surgery. *Surg Neurol.*

- 2006;65(2):136–143.
21. Adler N, Nachumovsky S, Meshulam-Derazon S, Ad-El D. Skin graft fixation with cyanoacrylate tissue adhesive in burn patients. *Burns*. 2007;33(6):803.
  22. Hallock GG. Expanded applications for octyl-2-cyanoacrylate as a tissue adhesive. *Ann Plast Surg*. 2001;46(2):185–189.
  23. Whitaker LA, Bartlett SP, Schut L, Bruce D. Craniosynostosis: An analysis of the timing, treatment, and complications in 164 consecutive patients. *Plast Reconstr Surg*. 1987;80(2):195-212.
  24. Imola MJ, Hamlar DD, Shao W, Chowdhury K, Tatum S. Resorbable plate fixation in pediatric craniofacial surgery: Long-term outcome. *Arch Facial Plast Surg*. 2001;3(2):79-90.
  25. Cavanaugh TB, Gottsch DJ. Infectious keratitis and cyanoacrylate adhesive. *Am J Ophthalmol*. 1991;111(4):466–472.
  26. Akcal MA, Poyanli O, Unay K, Esenkaya I, Gokcen B, Firatlıgil AS. Effect of N-butyl cyanoacrylate on fracture healing in segmental rat tibia fracture model. *J Orthop Surg Res*. 2014;9:76.
  27. Gonzalez E, Orta J, Quero C, et al. Ethyl-2-cyanoacrylate fixation of the cranial bone flap after craniotomy. *Surg Neurol*. 2000;53(3):288-289.
  28. Foresta E, Torroni A, Gasparini G, et al. Use of N-Butyl-2-Cyanoacrylate (Glubran2®) in fractures of orbital-maxillo-zygomatic complex. *J Maxillofac Oral Surg*. 2015;14(3):761-764.
  29. Eppley BL, Sadove AM, Havlik RJ. Resorbable plate fixation in pediatric craniofacial surgery. *Plast Reconstr Surg*. 1997;100(1):1-7;discussion 8-13.
  30. Orringer JS, Barcelona V, Buchman SR. Reasons for removal of rigid internal fixation devices in craniofacial surgery. *J Craniofac Surg*. 1998;9(1):40-44.