

## Combined Early Myelomeningocele Repair and Antibiotic-Impregnated Ventriculoperitoneal Shunt Insertion in Treatment of Chiari 2 Malformation with Overt Hydrocephalus: Outcome Analysis of 25 Consecutive Cases

Ahmed Y. Soliman,<sup>1</sup> Kareem Al Sharkawy,<sup>2</sup> Sherif Elkheshin<sup>1</sup>

<sup>1</sup>Department of Neurosurgery, Faculty of Medicine, Tanta University; <sup>2</sup>Department of Plastic Surgery, Faculty of Medicine, Tanta University, Tanta, EGYPT

Received: 23 June 2021 / Accepted: 2 October 2021 / Published online: 23 June 2022

**BACKGROUND:** Shunt infection represents a serious complication in patients undergoing repair of myelomeningocele (MMC) with overt hydrocephalus.

**OBJECTIVE:** This study aimed to assess the infection rate in patients who underwent combined early MMC repair with placement of antibiotic-impregnated shunt at the same setting.

**PATIENTS AND METHODS:** This retrospective study was carried out on live birth neonates with MMC and overt hydrocephalus who were admitted to Tanta University Hospitals during March 2014 throughout October 2019. All patients underwent simultaneous repair of MMC and placement of antibiotic-impregnated shunt within 48 hours after birth. Patients were followed up for six months postoperatively.

**RESULTS:** Twenty-five patients were included. Evans' index significantly decreased after surgery ( $0.34 \pm 0.03$  vs.  $0.29 \pm 0.02$ , respectively;  $p < 0.001$ ). Postoperative complications included partial wound dehiscence (12%) and infection (8%).

**CONCLUSION:** Antibiotic-impregnated shunts have a potential prophylactic role in the management of neonates with MMC and overt hydrocephalus. However, clinical trials with larger sample size and a control arm with standard shunts should be conducted to elucidate this effect.

**KEYWORDS:** Hydrocephalus, Infection, Myelomeningocele, Ventriculoperitoneal shunt.

### INTRODUCTION

Open neural tube defect is the most common and complex congenital malformation of the neuraxis. Incidence varies among studies, ranging from 0.7 to 5 per 1000 live births worldwide.<sup>1</sup> Myelomeningocele (MMC) is estimated to be the most common neural tube defect. Despite the improvement in prenatal care and the use of folic acid as a prophylactic measure, the prevalence of MMC is still considerable.<sup>2</sup> Hydrocephalus is an essential component of this malformation that may be detected before or after closure of MMC defect in 65-93% of patients with different follow-up stages. Neurological deficit associated with dysgenesis can occur in patients with MMC including the development of motor disorders, neurogenic bladder, and orthopedic deformities.<sup>3</sup> These complications have been associated with increased rates of morbidity and mortality in infants with MMC.

At time of birth, hydrocephalus is diagnosed in smaller percentage (5 to 10%) prior to defect repair.<sup>4</sup> With exposed

neural tube defects, many studies recommend repair of MMC sac during the first 24-48 hours to decrease the risk of infection. Late repair of MMC ( $\geq 48$  hours following birth) is associated with significant increase in mortality and morbidity rates.<sup>5-7</sup>

The strategy of intervention in infants presenting with MMC and clinically overt hydrocephalus is still a debatable issue. Some studies support sequential shunt placement and repair of MMC sac in two separate surgeries to decrease the risk of shunt infection.<sup>4,8</sup> However, other studies recommend simultaneous shunt insertion and repair of the defect at the same setting. The latter studies provide proofs that combined surgery is not associated with a higher rate of shunt infection and has a positive impact on the healing of back wound.<sup>9,10</sup> Therefore, the aim of the current study was to assess the infection rate in patients who underwent combined early MMC repair with placement of antibiotic-impregnated shunt at the same setting.

### PATIENTS AND METHODS

#### Study settings

This retrospective study was carried out on live birth neonates with MMC and overt hydrocephalus who were admitted to Tanta University Hospitals during March

#### Correspondence:

Ahmed Y. Soliman  
Department of Neurosurgery, Faculty of Medicine, Tanta University, Egypt  
E-mail: ahmadusuf0@yahoo.com

2014 throughout October 2019. The study attained approval from the Research Ethics Committee of the Faculty of Medicine, Tanta University. Informed consent was obtained from the parent of all individual participants included in the study. Confidentiality of the patients was kept by assigning code numbers to patients, which were known only to the principal investigator.

### Population

The study included all live born neonates with concomitant MMC having minimal or large part of the neural placode exposed (including myelosclerosis) and overt hydrocephalus who had clinically detectable suture diastasis with wide anterior fontanel and essentially considerable Evans' index higher than 0.30 measured by a neuroradiologist. Out of 392 live birth neonates with MMC in Tanta University Hospitals who were admitted during the specified study period, only 25 patients met our inclusion criteria. Cases with mild hydrocephalus and full thickness skin covering MMC sac were excluded as management may include elective surgery.

### Data collection

The collected preoperative clinical data included gestational age at birth, birth weight, length, size and location of the MMC defect, preoperative Evans' index, and timing in hours till surgery. Preoperative computed tomography (CT) scan and/or magnetic resonance imaging of the brain and spine were performed for all cases. Postoperative Evans' index was measured by neuro-radiologist through hospital picture archiving and communication system (PACS) in follow up CT brain at 6 months following surgery. Calculation of the body surface area of the whole infant was performed using the following equation: Body surface area =  $0.007184 \times \text{weight (in Kg)} \times 0.425 \times \text{height (in cm)} \times 0.725$ .<sup>11</sup>

Following the rule of nine applied in infants and young children, the whole back (dorsolumbar region, including buttocks) should represent 18% of total body surface area. The last step is the calculation of the MMC defect surface area. This surface area of the sac was then measured as percentage value in reference to the dorsolumbar region surface area. If this value is 7% or greater a skin flap is considered to close the defect. This may decrease the tension on sutures and avoid wound disruption with increased risk of infection. Otherwise a primary closure of the skin edges was considered.

### Preoperative preparation

All patients born by C-section and admitted to neonatal intensive care unit (NICU). Sterile dressing was applied and systemic antibiotic combination of cefotaxime + vancomycin immediately started. Preoperative preparation included echocardiography, full laboratory work-up, and CT scan of the brain and spine (as primary

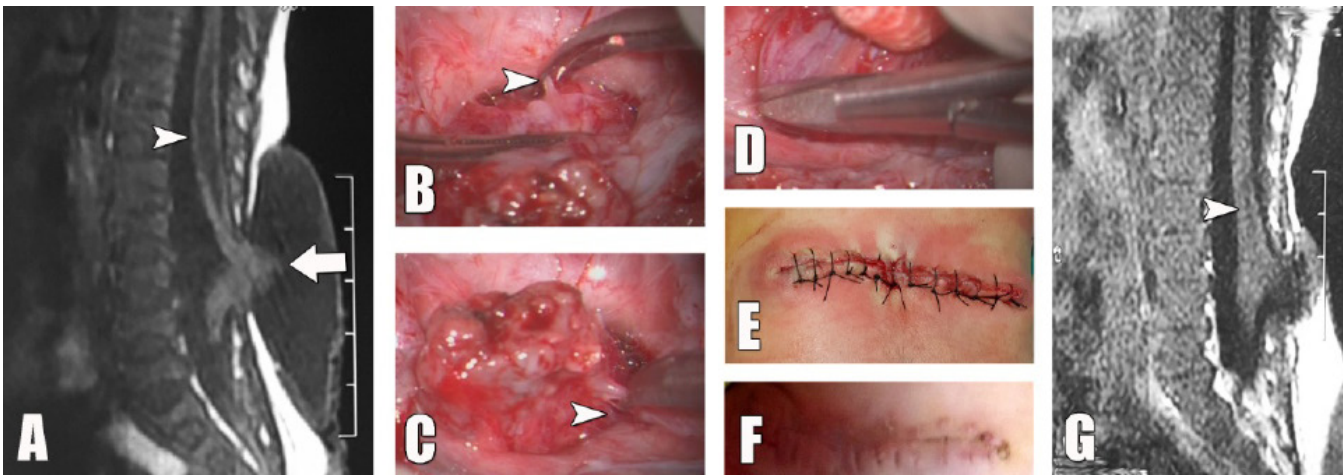
neuroradiological investigation). Magnetic resonance imaging (MRI) of the brain and whole spine was required for five patients to evaluate possible kinking of the cord in MMC sac, identify suspicious syrinx, and confirm trans-ependymal cerebrospinal fluid (CSF) permeation. All surgical procedures were performed early (not exceeding 48 hours post-natal). Prophylactic antibiotics (vancomycin and cefotaxime) were continued 6 days after surgery.

### Procedure

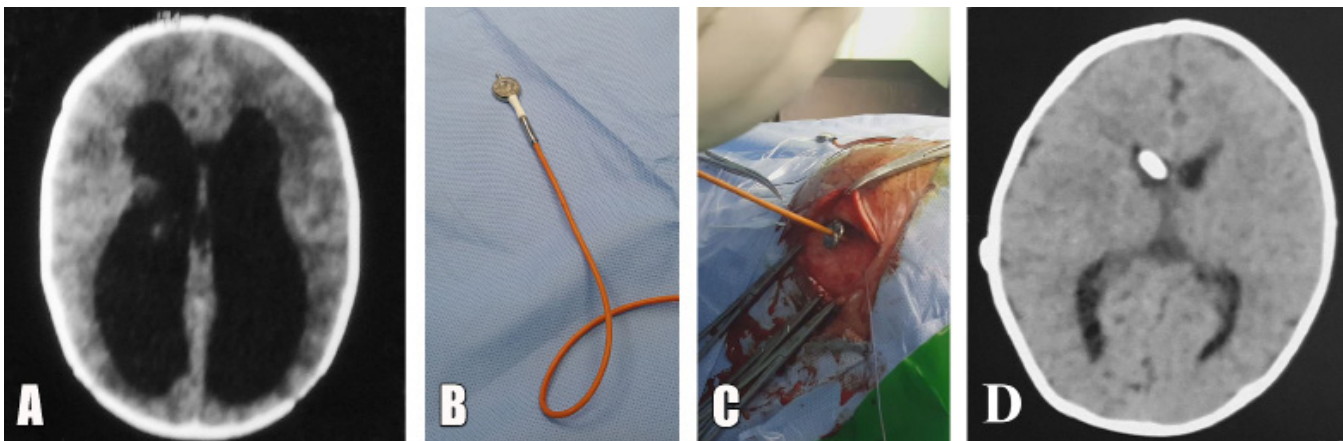
The patient was placed in prone position and surgical draping was performed as usual. The use of neurotoxic antiseptics was avoided as they may cause damage to the neural placode. Skin incision was started as close as possible to the full thickness skin layer. Under surgical microscopic view, splitting of skin from the dura was further performed. The neural placode was then separated from the dura at the zona epitheliosa and the neural structure was fully released. Intraoperative neurophysiological monitoring was performed to avoid neural damage. This included anal sphincters, quadriceps femoris, tibialis anterior, gastrocnemius and biceps femoris. To release kinked cord in some cases it was necessary to cut arachnoid bands fixing the neural placode and spinal cord with additional dentate ligament release if required. The dura was then closed overlaid. Duragen® (Integra LifeSciences, USA) was used in cases of wide dural defects (5 cases) which is further augmented by released both sides lumbar fascia second repair layer. The skin was closed either with primary closure or with skin flap according to the size of the defect as mentioned earlier. Rotational flaps were performed by plastic surgeon.

The patient was then put in supine position to insert ventriculoperitoneal (VP) shunt. We used a combination of ARES® antibiotic-impregnated both ventricular and peritoneal shunt tubes (Medtronic, USA) combined with valve system Miethke pediGAV® shunt system (Christoph Miethke GmbH & Co, Germany). All the patients underwent standard ventriculoperitoneal shunt placement with frontal precoronal mid-pupillary line proximal catheter incision and a trans-rectus mini-laparotomy incision for distal catheter. The gravity assisted unit was tunneled to a standard location in the retro-auricular area.

The minimum period for postoperative follow-up was 6 months to rule out infection that could be related to the procedures. Shunt infection has been verified by clinical findings (fever, shunt track erythema) and essentially confirmed by CSF sampling and analysis showing elevated total leukocytic count and positive bacterial culture. (Figs. 1, 2) demonstrate radiological findings, repair, and shunt insertion in two patients in our series.



**Fig 1:** (A) Sagittal T1 MRI of dorsolumbar region showing a MMC sac with the lower part of the spinal cord seen kinked and protruding through the defect (arrow) Immediately proximal to the cord’s kinked region, there is syringomyelia extending from the second lumbar to the tenth dorsal vertebrae (arrowhead) (B) Microsurgical repair of the myelomeningocele showing untethering of the cord’s left side by cutting arachnoid bands, including the dentate ligament (C) Microsurgical release of both the right and cranial portion of defect (D) Release of lower portion of the kinked cord is continued (E) Primary closure of the defect without the need of graft (F) Wound healing without disruption (G) Postoperative (3 months following surgery) sagittal T1 MRI of the dorsolumbar spine showing a near-total resolution of the syrinx with successful release of the kinked portion of the spinal cord.



**Fig 2:** (A) A preoperative axial CT image is showing overt hydrocephalus (B) Shunt hardware assembly with connection of the antibiotic-impregnated distal catheter to the Miethke® Pedi-GAV system (C) Freehand insertion of the proximal catheter into the lateral ventricle (D) Axial CT image of the brain shows resolution of ventriculomegaly and proximal catheter inside the frontal horn of the lateral ventricle.

**Postoperative care**

Patients were admitted to NICU and kept away from contact pressure on incisions for 5 days.

**Statistical analysis**

Statistical analysis was performed using Statistical Package for Social Sciences for Windows, version 26 (IBM Corp., Armonk, N.Y., USA). The Shapiro-Wilk test for normality was performed to determine the distribution of numerical data. For data that followed normal distribution, values were expressed as mean ± standard deviation. Comparisons between two paired groups were carried out using paired T-test. For data that did not follow normal distribution, the median, interquartile range (IQR: Expressed as 25<sup>th</sup>-75<sup>th</sup> percentiles), and range were calculated. For qualitative data, the variables were summarized as frequencies (count and percentage). Pearson’s Chi square test for independence, was used to assess the association between two categorical variables.

A p value ≤ 0.05 was adopted for interpretation of statistical significance.

**RESULTS**

The present study included 25 patients with meningocele and hydrocephalus. **Table 1** shows the characteristics of the studied patients. Male patients constituted 56%, while female patients accounted for 44%. The mean gestational age was 37.8±1.5 weeks, ranging from 35 to 40 weeks. Six (24%) patients were preterm, while the remaining 19 (76%) were full-term. The mean birth weight was 2940±552.3, ranging from 1600 to 3800 g. Only 3 (12%) patients were of low birth weight (<2500 g) whereas 22 (88%) patients were of average birth weight. The mean body length, body surface area, and surface area of the dorsolumbar region of the studied patients were 47.0±2.9 cm, 1850.8±231.9 cm<sup>2</sup>, and 333.1±41.7 cm<sup>2</sup>, respectively. The most common site of defect was in lumbar region (n=11, 44%), followed by lumbodorsal

(n=9, 36%), and then lumbosacral region (n=5, 20%). The median defect size was 12.6 cm<sup>2</sup>, ranging from 3.5-47.1 cm<sup>2</sup>. The median percent of defect to dorsolumbar surface area was 3.8%, ranging from 1 - 11.8%. Patients were categorized according to the percent of defect to dorsolumbar surface area into two groups: those with percent less than 7% (n=17, 68%) and those with percent 7% or above (n=8, 32.0%). Calculation of the percent of defect to dorsolumbar surface area is crucial to determine the type of repair. A percent <7% indicated feasibility of primary repair, whereas a percent >7% indicated the need of rotational flap. No other anomalies were detected except for scoliosis in one patient and Fallot's tetralogy in another patient.

**Tables 2, 3** summarize the operative and postoperative data of the studied series of patients. The repair was primary in 17 patients (68%), while skin flap was performed in 8 patients (32%). Preoperative Evans' index in all patients was above 0.3, with a mean value of 0.34±0.03. The mean postoperative Evans' index was significantly reduced to 0.29±0.02 (p<0.001), with 21 patients (84%) ≤0.3 and 4 patients (16%) with index

above 0.3. The mean difference between preoperative and postoperative Evans' index was 0.056±0.025. The mean time to surgery was 28.7±9.9 hours, with a maximum delay of 48 hours. Postoperative complications were detected in 3 (12%) patients in the form of partial wound dehiscence (n=3, 12%) and CSF infection (n=2, 8%).

**Table 4** demonstrates the characteristics of the three patients who suffered from postoperative complications. Two of the patients were females while one patient was a male. The three patients were preterm; two of them had low birth weight. The defect was lumbodorsal in two patients with a size above the median of our series, whereas the third patient had a lumbar defect with a size equal to the median. The percentage of the defect to dorsolumbar surface area was above the median of our series in the three patients. Two patients underwent repair with skin flap, while the third had primary repair. The difference between preoperative and postoperative Evans' index was minimal in two patients and null in one patient, with only one patient having Evans' index below 0.3. The time to surgery was relatively longer than other patients in the series (the shortest time was 40 hours).

**Table 1: Patients' preoperative characteristics (Total n = 25)**

Parameter	All patients (n = 25)
<b>Gender</b>	
Female	11 (44.0%)
Male	14 (56.0%)
<b>Gestational age (Weeks)</b>	
Mean ± SD (Range)	37.8 ± 1.5 (35.0 - 40.0)
Preterm	6 (24.0%)
Full-term	19 (76.0%)
<b>Birth weight (grams)</b>	
Mean ± SD (Range)	2940.0 ± 552.3 (1600.0 - 3800.0)
Low birth weight	3 (12.0%)
Normal birth weight	22 (88.0%)
<b>Length (cm)</b>	
Mean ± SD (Range)	47.0 ± 2.9 (40.0 - 52.0)
<b>Body surface area (cm<sup>2</sup>)</b>	
Mean ± SD (Range)	1850.8 ± 231.9 (1270.0 - 2220.0)
Surface area of dorsolumbar region (cm <sup>2</sup> )	
Mean ± SD (Range)	333.1 ± 41.7 (228.6 - 399.6)
<b>Location of defect</b>	
Lumbar	11 (44.0%)
Lumbodorsal	9 (36.0%)
Lumbosacral	5 (20.0%)
<b>Size of defect (cm<sup>2</sup>)</b>	
Median [IQR] (Range)	12.6 [9.4 - 22.0] (3.5 - 47.1)
<b>% of defect to dorsolumbar region surface area</b>	
Median [IQR] (Range)	3.8 [2.8 - 7.3] (1.0 - 11.8)
<7%	17 (68.0%)
≥7%	8 (32.0%)
<b>Other spinal anomalies</b>	
Scoliosis	1 (4.0%)
<b>Congenital anomaly</b>	
Fallot's tetralogy	1 (4.0%)

IQR: Interquartile range; SD: Standard deviation; n: Number.

**Table 2: Operative and postoperative data in the studied patients (Total n = 25)**

Parameter	All patients (n = 25)
<b>Repair type</b>	
Primary	17 (68.0%)
Skin flap	8 (32.0%)
<b>Preoperative Evan's index</b>	
Mean ± SD (Range)	0.34 ± 0.03 (0.31 - 0.40)
<b>Postoperative Evan's index</b>	
Mean ± SD (Range)	0.29 ± 0.02 (0.26 - 0.36)
<b>Time to surgery (hours)</b>	
Mean ± SD (Range)	28.7 ± 9.9 (10.0 - 48.0)
<b>Postoperative complications</b>	
Partial wound dehiscence	3 (12.0%)
Infection of CSF	2 (8.0%)

SD: Standard deviation; n: Number; CSF: Cerebrospinal fluid.

**Table 3: Comparison of Evan's index before and after surgery**

	Preoperative	Postoperative	Difference	p
Evans' index	0.34 ± 0.03	0.29 ± 0.02	0.056 ± 0.025	<0.001*
Mean ± SD (Range)	(0.31 - 0.40)	(0.26 - 0.36)	(0.000 – 0.100)	

\*Significant; SD: Standard deviation.

**Table 4: Characteristics of patients with complications (Total n = 3)**

	Patient 1	Patient 2	Patient 2
Gender	Female	Male	Female
Gestational age (weeks)	35	36	36
Birth Weight (grams)	1850	1600	2500
Site of defect	Lumbodorsal	Lumbodorsal	Lumbar
size of defect (cm <sup>2</sup> )	18.9	18.9	12.6
% of defect to dorsolumbar surface area	7.5%	8.2%	4.2%
Repair type	Skin flap	Skin flap	Primary
Preoperative Evan's index	0.37	0.32	0.32
Postoperative Evan's index	0.36	0.32	0.29
Other anomalies		Fallot tetralogy	Scoliosis
Time to surgery (hours)	40	48	46
Postoperative complications	Partial wound dehiscence & CSF infection	Partial wound dehiscence & CSF infection	Partial wound dehiscence

n: Number. CSF: Cerebrospinal fluid.

**DISCUSSION**

Myelomeningocele is the most common anatomical form of spina bifida. In MMC, a bony defect exists along with a lack of skin covering, resulting in exposure of neural tissue and membrane to the external environment. The bony and skin defects increase the risk of bacterial colonization and infection of the central nervous system, with the grave consequences of impaired mental development or mortality.<sup>12</sup> High mortality rates, ranging from 65 to 75% were reported in untreated patients within the first 6 months of life.<sup>13</sup> Only 5-10% of MMC cases present with clinically overt hydrocephalus at birth.<sup>4</sup>

The gravity of MMC mandates early management to improve patient's outcomes. Management of MMC with clinically overt hydrocephalus in infants involves the placement of ventriculoperitoneal shunt and repair of MMC sac. These two procedures can be performed either simultaneously in the same surgical setting or sequentially in two separate sessions.<sup>4,8,14</sup>

Shunt infection is a serious, potentially life-threatening complication that should be prevented.<sup>9,10</sup> Consequences of shunt infection include scarring and loculation of the ventricles resulting in augmentation of hydrocephalus, and thereby may lead to increased risk of seizures as well

as mental and psychomotor retardation.<sup>15,16</sup>

Shunt placement when precedes MMC repair may increase the risk of infection by allowing reverse flow of the CSF from the lumbar region (exposed MMC sac) to the ventricles.<sup>7,17</sup> In addition, it has been postulated that the MMC sac can be colonized by microorganisms and hence may predispose to shunt infection. Much scientific debate exists as regards the potential association between the time of intervention and performance of the combined procedures on one hand, and increased risk of shunt infection on the other hand.

Delayed shunt insertion in a separate session at least 3 to 7 days after MMC repair has been advocated by some studies. In order to avoid the potential higher risk of infection and shunt failure following the simultaneous approach, especially that patients with mild, non-progressive hydrocephalus may not require shunting.<sup>4,7,9,18</sup> According to these studies, the simultaneous approach may increase the risk of infection through CSF exposure and the occurrence of transient bacteremia during operating on MMC. The administration of antibiotics after MMC repair may reduce the likelihood of infection with delayed shunt insertion.

On the other hand, other studies.<sup>9,18-20</sup> have supported the simultaneous MMC repair and shunting, arguing that the simultaneous approach is associated with more rapid recovery, prevents further brain damage which may develop during the delay period, shortens the length of hospital stay, and is associated with lower risk of CSF leakage. The risk of infection in the simultaneous approach is controversial, as most studies which compared the rates of infection between the two approaches did not report a significant difference.<sup>8,10,14,18,19</sup> Moreover, a recent meta-analysis demonstrated the lack of significant difference between simultaneous and delayed approaches as regards the rates of shunt failure and infection, whereas the delayed approach was associated with shunt failure.<sup>21</sup>

We believe that both hydrocephalus and the back sac of MMC are essentially linked components of Chiari II malformation whose management should be as early and appropriate as possible. We hypothesized that early simultaneous repair of MMC could be performed, while minimizing the risk of shunt infection by using antibiotic-impregnated shunts. The aim of the present study was to assess the infection rate in patients who underwent combined early MMC repair with placement antibiotic-impregnated shunt at the same setting. We used antibiotic-impregnated shunts that release rifampin and clindamycin. The combination of these two antibiotics was found to reduce colonization with Gram-positive bacteria for up to 127 days *in vivo*.<sup>22,23</sup>

A meta-analysis in 2014 included 6 studies comparing the use of antibiotic-impregnated shunts with standard shunt in children and stated that antibiotic-impregnated shunts resulted in decreased risk of infection (risk ratio: 0.51; 95% confidence interval (CI): 0.29–0.89;  $p < 0.001$ ).<sup>24</sup>

The present study included 25 patients with MMC and overt hydrocephalus. Ventricular enlargement was evaluated preoperatively by measuring Evans' index, which represents the ratio between the maximal width of the frontal horns and the maximal width of the inner table of the cranium at the level of the frontal horns.<sup>25</sup> All our patients had an Evans' index above 0.3, which indicates ventricular enlargement not entirely caused by cerebral atrophy or congenital enlargement. This constitutes one of the criteria for selecting shunt-responsive patients.<sup>26,27</sup>

The repair of MMC with overt hydrocephalus is recommended to be performed within the first 48 to 72 hours after birth.<sup>28,29</sup> Late MMC repair has been associated with increased risk of shunt revision due to shunt occlusion with increased circulating proteins and debris in CSF.<sup>18,30</sup> Moreover, MMC repair after a delay more than 48 hours was associated with a higher incidence of infection,<sup>31</sup> morbidity, and mortality.<sup>5-7</sup> Cherian et al.<sup>32</sup> recommended that surgery for MMC should be performed on the second day of life, as surgeries performed on the first day were associated with significantly higher rates of postoperative complications. Therefore, in the present study, we decided to perform surgery within 48 hours after birth (the mean time to surgery:  $28.7 \pm 9.9$  hours).

Repair of the skin defect of MMC may be performed by primary closure or use of flaps. Primary closure is performed by undermining of the wound margins and can be accomplished in approximately 75% of cases. The use of flaps is required in the remaining cases in which the defects are too large to be managed by primary closure.<sup>33,34</sup> Primary closure of large skin defects may cause enhanced tethering, skin necrosis, suture detachment, and infections.<sup>35,36</sup>

Several types of flap can be used including cutaneous, muscular, musculocutaneous as well as bone and muscle flaps.<sup>35-37</sup> There is no consensus in the literature on when primary closure or a flap should be used to repair skin defects. Several factors affect the choice of repair method by surgeon including the defect's size, shape, and the amount of adequate soft tissue around the defect.<sup>36,37</sup> Regardless of the method, successful repair should be tension-free and should provide good soft-tissue padding of the neural tube, prevent CSF leakage, and provide stable and durable wound healing.<sup>36</sup>

Prior to surgery, we calculated the sac surface area and percentage of whole patient back to decide if this defect would be primarily closed or a skin flap should be considered for closure. Ozveren et al.<sup>36</sup> in their study of 32 infants with myelomeningocele repair declared that it was not possible to perform primary repair of any defect occupying more than 8% of the thoracolumbar area. Despite their organized defect size percentage calculation, three out of twenty cases of primary closure subjected to wound dehiscence, which we believe it may add a risk on VP shunt. To avoid this case scenario we have chosen a lower percentage value of 7% for primary closure. If the percentage of the sac surface area to

whole back surface area was 7% or greater, a skin flap was chosen for closure. In either case, a plastic surgeon performed the repair, avoiding any tension on the wound to decrease the risk of wound dehiscence which would expose the shunt and increase the likelihood of infection.

Musculocutaneous flaps were advocated by some researchers for management of large MMC defects. However, high complication rates were reported in association with the use of musculocutaneous flap to cover large lumbosacral MMC defects.<sup>5</sup> We preferred to use skin flaps in cases in which primary closure was not appropriate. Compared to musculocutaneous flaps, skin flaps are easier to perform with less operative time and less blood loss. Successful use of skin flaps was also described in management of large MMC defects.<sup>38,39</sup>

The overall outcome of our series of patients was satisfactory and ventricular enlargement was significantly reduced postoperatively as inferred from the comparison between preoperative and postoperative Evans' index ( $0.34 \pm 0.03$  vs.  $0.29 \pm 0.02$ , respectively;  $p < 0.001$ ).

Postoperative complications of MMC wound closure were reported in the literature, with rates ranging from 7.7% to 33%. The most frequent complications are CSF leak, meningitis, seroma, hematoma, skin flap necrosis, wound infection, and dehiscence.<sup>32,40</sup> Complications were encountered in three cases only (12%) in our series. The three cases had partial wound dehiscence with no growth in bacterial culture obtained from the wound, and two of them (8% of total cases) had shunt infection. There was very slight difference between preoperative and postoperative Evans' index in those patients, which may suggest non-functioning shunt. However, Evan's index may not reflect the postoperative decrease in ventricular enlargement in some cases.<sup>41,42</sup> Failure of infection prophylaxis in the two patients could be explained by contamination of other devices used in the shunt such as the valve and the reservoir which are not antibiotic-impregnated. Other potential factors that may make the patients more susceptible to infection are skin ulcerations and wound dehiscence.

The reported rates of shunt infection in pediatric patients following repair of MMC and hydrocephalus varied widely among previous studies. The rates of shunt infection following simultaneous procedures ranged from as low as 5.2% up to 25.8%.<sup>5,17,18,43</sup> The rates of shunt infection following consecutive separate procedures were generally lower than those of simultaneous procedures, but also widely varied, ranging from null up to 9.5%.<sup>7,17</sup>

Comparing the outcomes (infection rate and wound dehiscence) among the present study and two relevant studies; the groups in the two studies included simultaneous and delayed shunt insertion. Both studies were conducted on neonates with MMC and hydrocephalus who underwent repair within 48 hours after birth. Infection rate was lower in the present study (8%) compared to simultaneous shunting in the studies

by Gurbuz & Yuksel,<sup>14</sup> (13.6%) and Arslan et al.<sup>4</sup> (12.3%) as well as separate shunting in the study by Gurbuz & Yuksel,<sup>14</sup> (9.5%). However, these differences did not reach statistical significance ( $P=0.704$ ). As regards partial wound dehiscence after repair, the rate was 12% in the present study compared to 4.6% in the simultaneous shunting group and 17.2% in the separate shunting group in the study by Arslan et al.<sup>4</sup>

Contradictory reports have been published as regards the effect of performing separate or simultaneous procedures on the rates of shunt infection in patients with overt hydrocephalus and MMC. We compared the rates of infection in the present study to those reported by two relevant studies. Both studies included simultaneous and delayed shunt insertion in neonates with MMC and hydrocephalus which were performed within 48 hours after birth. The principal difference between the present study and the other two studies is that antibiotic-impregnated shunt was used in our cohort. The infection rate was lower in the present study (8%) than those reported following simultaneous shunting (12.3%-13.6%).<sup>4,14</sup> as well as separate shunting (9.5%).<sup>14</sup> However, these differences were not statistically significant.

## CONCLUSION

Our results suggest a potential prophylactic role for antibiotic-impregnated shunts in the management of neonates with MMC and overt hydrocephalus. However, clinical randomized prospective trials with larger sample size and a control arm with standard shunts should be conducted to elucidate this effect.

## List of abbreviations

CI: Confidence interval  
 CSF: Cerebrospinal fluid.  
 CT: Computed tomography.  
 IQR: Interquartile range.  
 MMC: Myelomeningocele.  
 MRI: Magnetic resonance imaging.  
 NICU: Neonatal intensive care unit.  
 PACS: Picture archiving and communication system.  
 SD: Standard deviation.  
 VP: Ventriculo-peritoneal.

## Disclosure

The authors report no conflict of interest in the materials or methods used in this study or the findings specified in this paper.

## Funding

The authors received no financial support for the research, authorship, and/or publication of this paper.

## Acknowledgment

We would like to thank the medical statistical unit at Tanta University Hospitals for their great help in data interpretations.

## REFERENCES

1. Alatas I, Canaz G, Kayran NA, Kara N, Canaz H. Shunt revision rates in myelomeningocele patients in the first year of life: A retrospective study of 52 patients. *Childs Nerv Syst.* 2018;34(5):919-923.
2. Botto LD, Lisi A, Robert-Gnansia E, et al. International retrospective cohort study of neural tube defects in relation to folic acid recommendations: Are the recommendations working? *BMJ.* 2005;330(7491):571.
3. Bowman RM, Boshnjaku V, McLone DG. The changing incidence of myelomeningocele and its impact on pediatric neurosurgery: A review from the Children's Memorial Hospital. *Childs Nerv Syst.* 2009;25(7):801-806.
4. Arslan M, Esegolu M, Gudu BO, et al. Comparison of simultaneous shunting to delayed shunting in infants with myelomeningocele in terms of shunt infection rate. *Turk Neurosurg.* 2011;21(3):397-402.
5. Brau RH, Rodríguez R, Ramírez MV, González R, Martínez V. Experience in the management of myelomeningocele in Puerto Rico. *J Neurosurg.* 1990;72(5):726-731.
6. Miller PD, Pollack IF, Pang D, Albright AL. Comparison of simultaneous versus delayed ventriculoperitoneal shunt insertion in children undergoing myelomeningocele repair. *J Child Neurol.* 1996;11(5):370-372.
7. Oktem IS, Menkü A, Ozdemir A. When should ventriculoperitoneal shunt placement be performed in cases with myelomeningocele and hydrocephalus? *Turk Neurosurg.* 2008;18(4):387-391.
8. Parent AD, McMillan T. Contemporaneous shunting with repair of myelomeningocele. *Pediatr Neurosurg.* 1995;22(3):132-135.
9. Bell WO, Arbit E, Fraser RA. One-stage meningomyelocele closure and ventriculoperitoneal shunt placement. *Surg Neurol.* 1987;27(3):233-236.
10. Radmanesh F, Nejat F, El Khashab M, Ghodsi SM, Ardebili HE. Shunt complications in children with myelomeningocele: Effect of timing of shunt placement. Clinical article. *J Neurosurg Pediatr.* 2009;3(6):516-520.
11. Du Bois D, Du Bois EF A. Formula to estimate the approximate surface area if height and weight be known. *Arch Intern Med.* 1916;17:863-871.
12. Ntimbani J, Kelly A, Lekgwara P. Myelomeningocele - A literature review. *Interdiscip Neurosurg: Adv Tech Case Manag.* 2020;19:100502.
13. Luce EA, Walsh J. Wound closure of the myelomeningocele defect. *Plast Reconstr Surg.* 1985;75(3):389-393.
14. Gurbuz MS, Yuksel MO. The association between the timing of shunt placement and shunt infection in hydrocephalus associated with myelomeningocele. *Turk Neurosurg.* 2020;30(1):94-98.
15. Jamjoom AB, Mohammed AA, al-Boukai A, Jamjoom ZA, Rahman N, Jamjoom HT. Multiloculated hydrocephalus related to cerebrospinal fluid shunt infection. *Acta Neurochir (Wien).* 1996;138(6):714-719.
16. Chaddock W, Adametz J. Incidence of seizures in patients with myelomeningocele: A multifactorial analysis. *Surg Neurol.* 1988;30(4):281-285.
17. Caldarelli M, Di Rocco C, La Marca F. Shunt complications in the first postoperative year in children with meningomyelocele. *Childs Nerv Syst.* 1996;12(12):748-754.
18. Tuli S, Drake J, Lamberti-Pasculli M. Long-term outcome of hydrocephalus management in myelomeningoceles. *Childs Nerv Syst.* 2003;19(5):286-291.
19. Machado HR, Santos de Oliveira R. Simultaneous repair of myelomeningocele and shunt insertion. *Childs Nerv Syst.* 2004;20(2):107-109.
20. Wakhlu A, Wakhlu G, Saxena S, Tandon RK. Single-stage treatment of spina bifida with hydrocephalus based on a prediction rule derived from preoperative cranial ultrasound. *Pediatr Neurosurg.* 2009;45(4):271-275.
21. McCarthy DJ, Sheinberg DL, Luther E, McCrea HJ. Myelomeningocele-associated hydrocephalus nationwide analysis and systematic review. *Neurosurg Focus.* 2019;47(4):E5.
22. Bayston R, Ashraf W, Bhundia C. Mode of action of an antimicrobial biomaterial for use in hydrocephalus shunts. *J Antimicrob Chemother.* 2004;53(3):778-782.
23. Pattavilakom A, Kotasnas D, Korman TM, Xenos C, Danks A. Duration of in vivo antimicrobial activity of antibiotic-impregnated cerebrospinal fluid catheters. *Neurosurgery.* 2006;58(5):930-935.
24. Klimo P, Jr., Thompson CJ, Baird LC, Flannery AM. Pediatric hydrocephalus: Systematic literature review and evidence-based guidelines. Part 7: Antibiotic-impregnated shunt systems versus conventional shunts in children: A systematic review and meta-analysis. *J Neurosurg Pediatr.* 2014;14(Suppl\_1):53-59.
25. Evans WA, Jr. An encephalographic ratio for estimating ventricular enlargement and cerebral atrophy. *Arch Neurol Psychiatry.* 1942;47(6):931-937.



26. Tarnaris A, Kitchen ND, Watkins LD. Noninvasive biomarkers in normal pressure hydrocephalus: Evidence for the role of neuroimaging. *J Neurosurg.* 2009;110(5):837-851.
27. Relkin N, Marmarou A, Klinge P, Bergsneider M, Black PM. Diagnosing idiopathic normal-pressure hydrocephalus. *Neurosurgery.* 2005;57(3 Suppl): S4-16.
28. Bulbul A, Can E, Bulbul LG, Cömert S, Nuhoglu A. Clinical characteristics of neonatal meningomyelocele cases and effect of operation time on mortality and morbidity. *Pediatr Neurosurg.* 2010;46(3):199-204.
29. Messing-Jünger M, Röhrig A. Primary and secondary management of the Chiari II malformation in children with myelomeningocele. *Childs Nerv Syst.* 2013;29(9):1553-1562.
30. Talamonti G, D'Aliberti G, Collice M. Myelomeningocele: Long-term neurosurgical treatment and follow-up in 202 patients. *J Neurosurg.* 2007;107(5 Suppl):368-386.
31. Attenello FJ, Tuchman A, Christian EA, et al. Infection rate correlated with time to repair of open neural tube defects (myelomeningoceles): An institutional and national study. *Childs Nerv Syst.* 2016;32(9):1675-1681.
32. Cherian J, Staggars KA, Pan IW, Lopresti M, Jea A, Lam S. Thirty-day outcomes after postnatal myelomeningocele repair: A national surgical quality improvement program pediatric database analysis. *J Neurosurg Pediatr.* 2016;18(4):416-422.
33. Ulusoy MG, Koçer U, Sungur N, et al. Closure of meningomyelocele defects with bilateral modified V-Y advancement flaps. *Ann Plast Surg.* 2005;54(6):640-644.
34. Patterson TJ. The use of rotation flaps following excision of lumbar myelo-meningoceles: An aid to the closure of large defects. *Br J Surg.* 1959;46(5):606-608.
35. Ramirez OM, Ramasastry SS, Granick MS, Pang D, Futrell JW. A new surgical approach to closure of large lumbosacral meningomyelocele defects. *Plast Reconstr Surg.* 1987;80(6):799-809.
36. Ozveren MF, Erol FS, Topsakal C, Tiftikci MT, Akdemir I. The significance of the percentage of the defect size in spina bifida cystica in determination of the surgical technique. *Childs Nerv Syst.* 2002;18(11):614-620.
37. Kemaloğlu CA, Özyazgan İ, Ünverdi ÖF. A decision-making guide for the closure of myelomeningocele skin defects with or without primary repair. *J Neurosurg Pediatr.* 2016;18(2):187-191.
38. Akan IM, Ulusoy MG, Bilen BT, Kapucu MR. Modified bilateral advancement flap: The slide-in flap. *Ann Plast Surg.* 1999;42(5):545-548.
39. Cruz NI, Ariyan S, Duncan CC, Cuono CB. Repair of lumbosacral myelomeningoceles with double Z-rhomboid flaps. Technical note. *J Neurosurg.* 1983;59(4):714-717.
40. Mangels KJ, Tulipan N, Bruner JP, Nickolaus D. Use of bipedicular advancement flaps for intrauterine closure of myeloschisis. *Pediatr Neurosurg.* 2000;32(1):52-56.
41. Meier U, Paris S, Gräwe A, Stockheim D, Hajdukova A, Mutze S. Is there a correlation between operative results and change in ventricular volume after shunt placement? A study of 60 cases of idiopathic normal-pressure hydrocephalus. *Neuroradiology.* 2003;45(6):377-380.
42. Mocco J, Tomey M, Komotar R, Mack W, Frucht S, Goodman R. Ventriculoperitoneal shunting of idiopathic normal pressure hydrocephalus increases midbrain size: A potential mechanism for gait improvement. *Neurosurgery.* 2006;59(5):847-851.
43. McLone DG, Dias MS. Complications of myelomeningocele closure. *Pediatr Neurosurg.* 1991;17(5):267-273.